

Histopathological changes in fish intestine and application of mucosal cells as novel histopathological markers

Josip Barišić, PhD, DVM
Wellfish Diagnostics Ltd.

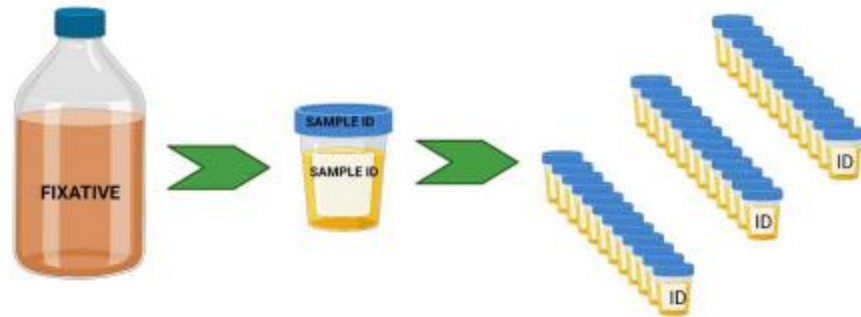
THIRD PROJECT MEETING

Integrated evaluation of aquatic organism responses to metal exposure: gene expression, bioavailability, toxicity and biomarker responses (BIOTOXMET)

Zagreb, 19th May 2023



Protocole for histopathology sampling

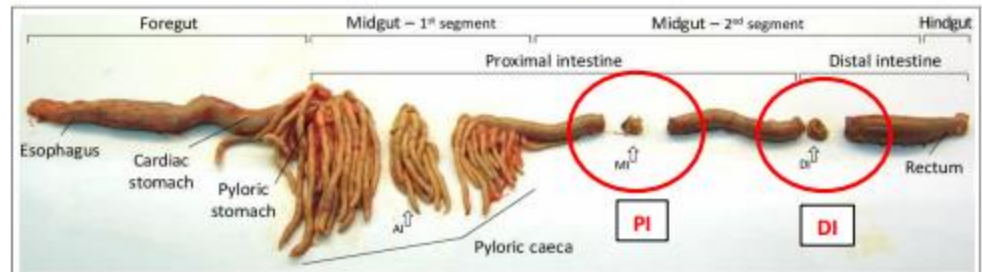


1. Label each sample cup (ID) on the lid and on the cup. Prepare 10 cups per sampling point (site). Total 30 cups for each field trip.
2. Pour Modified Hartmann/Davidson fixative (Biognost) into each sample cup, to make it half full (30-40 mL). Doesn't have to be precise. Tightly close the lid. Keep all chemicals on room temperature.
3. On the field you will need: pair of scissors and scalpel to cut tissues and pair of tweezers

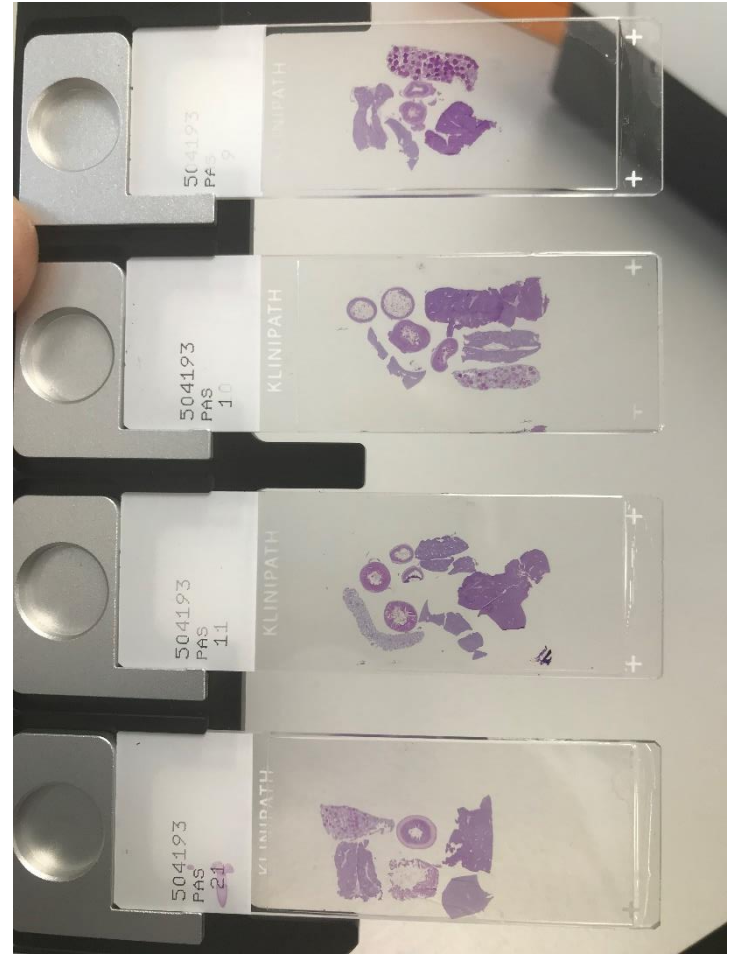

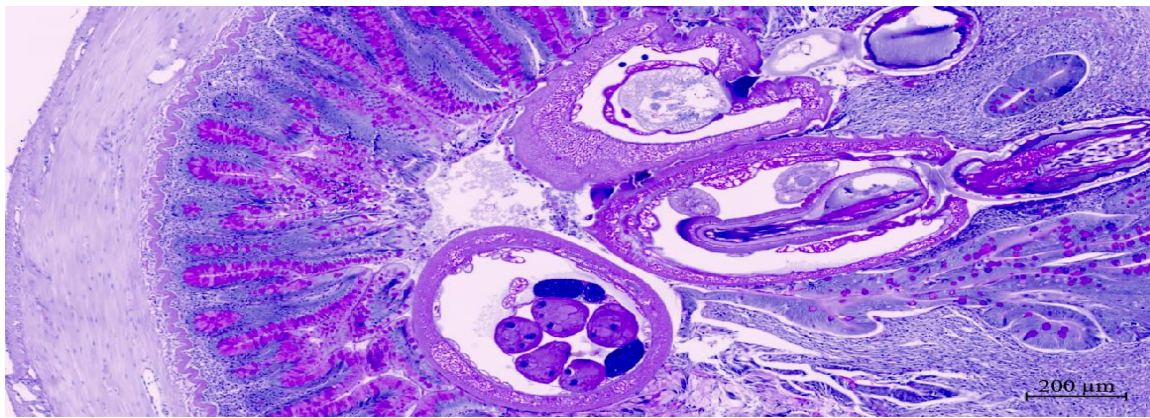
4. From intestine please take two parts – proximal and distal (0.5 cm size)

Orientation: 2 cm from the last pyloric caeca (PI) –PROXIMAL INTESTINE
2 cm before rectum (DI) – DISTAL INTESTINE

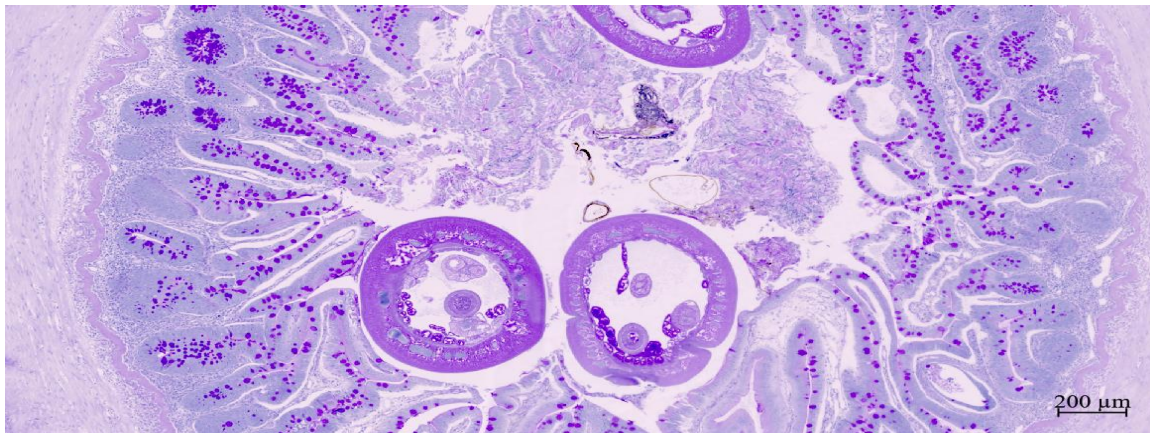


Histopathology processing

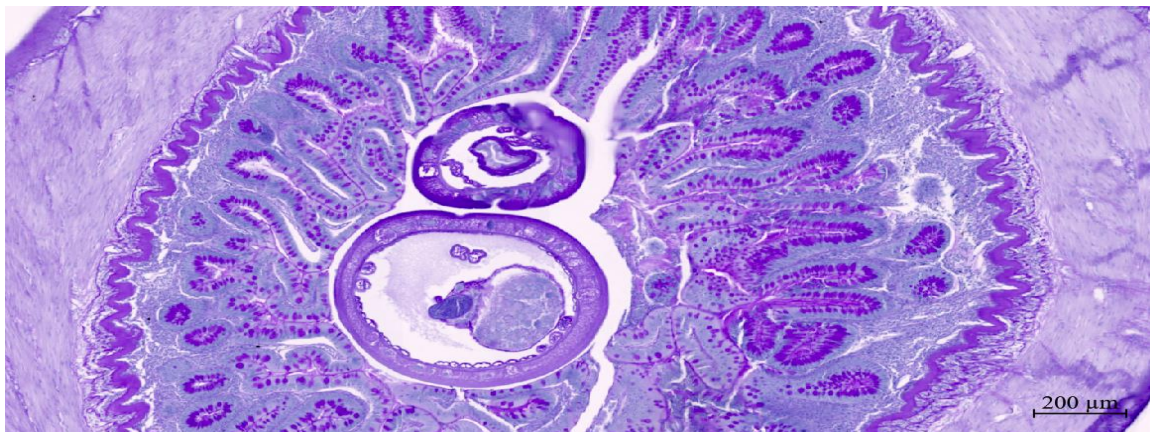




MILJACKA (KNP)

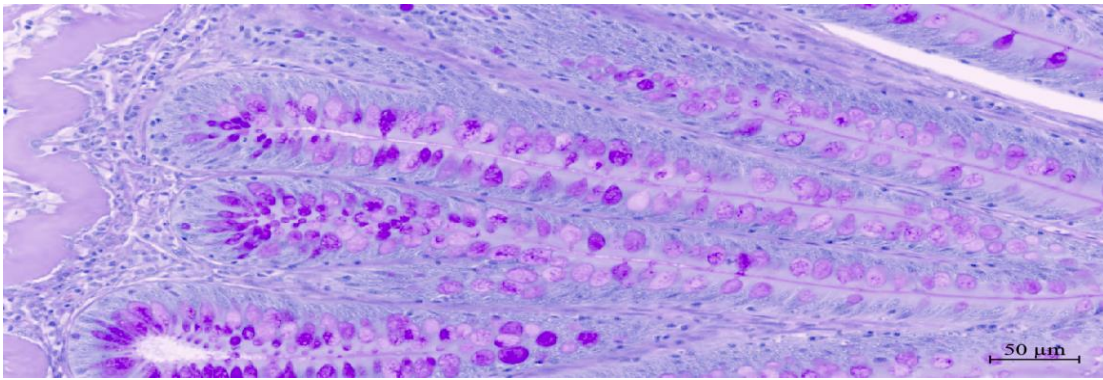


KNIN

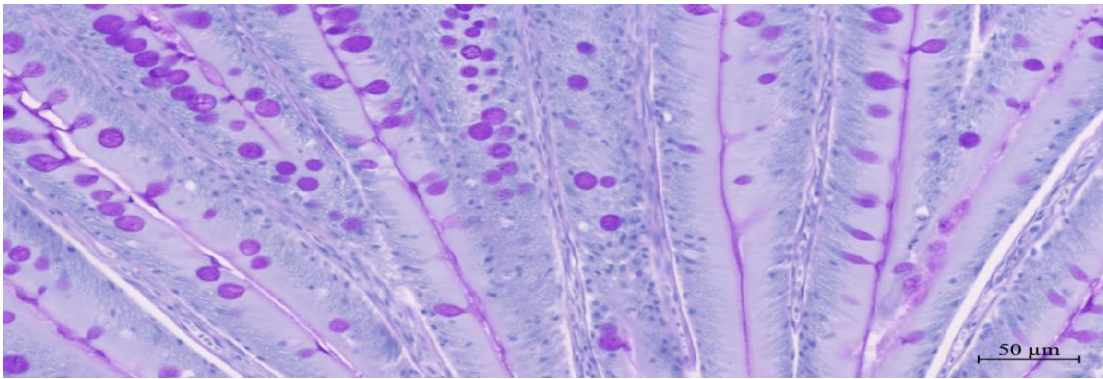


KRKA SOURCE

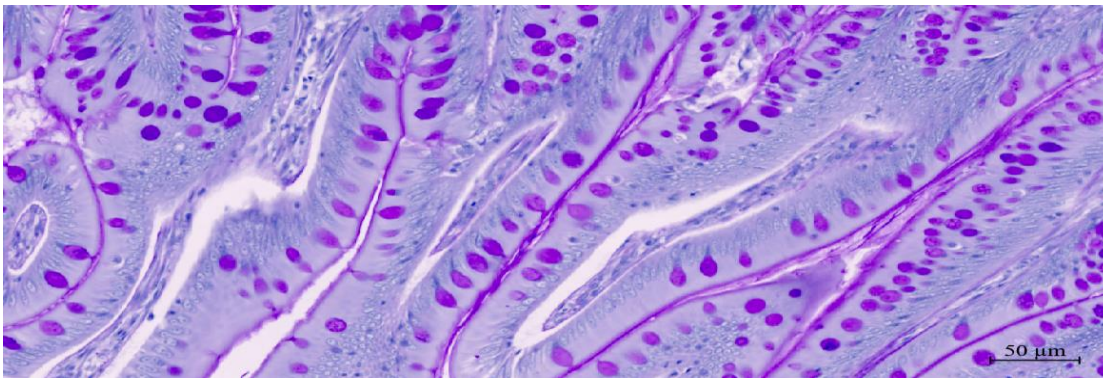
INTESTINES



MILJACKA (KNP)



KNIN



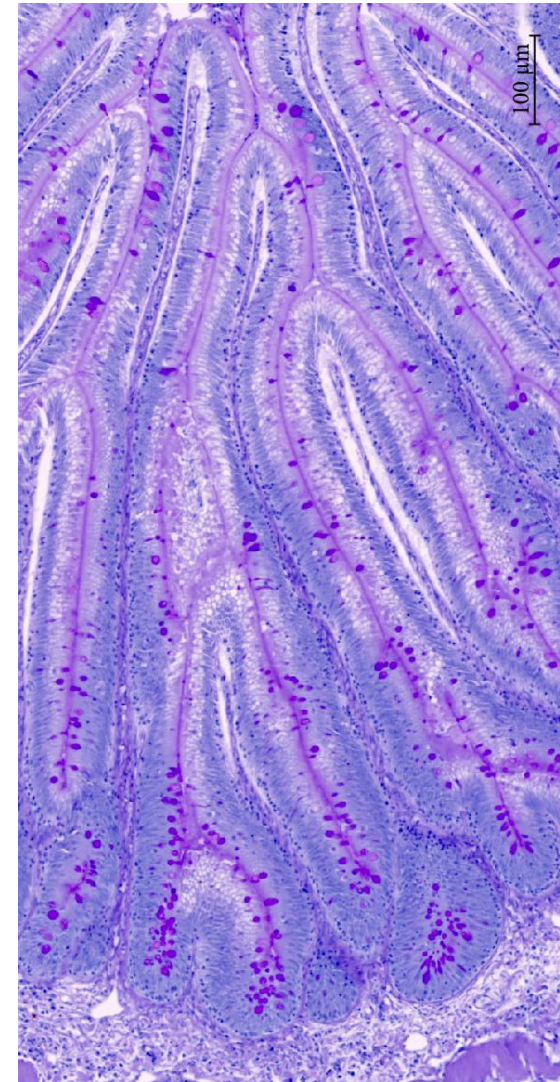
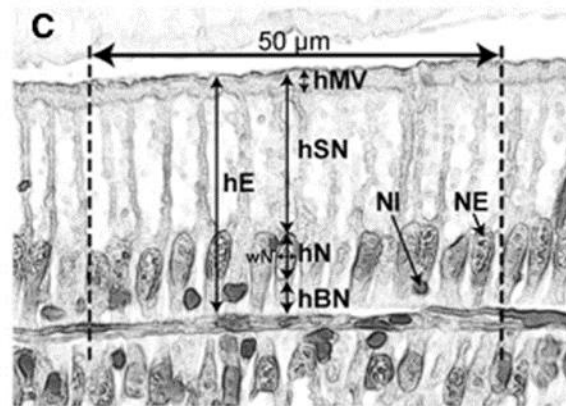
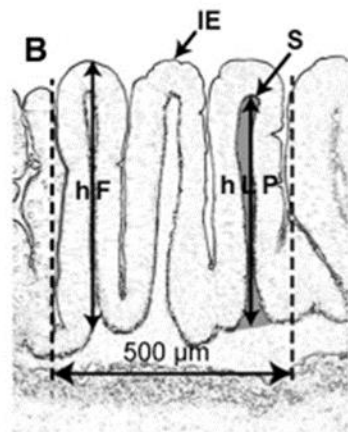
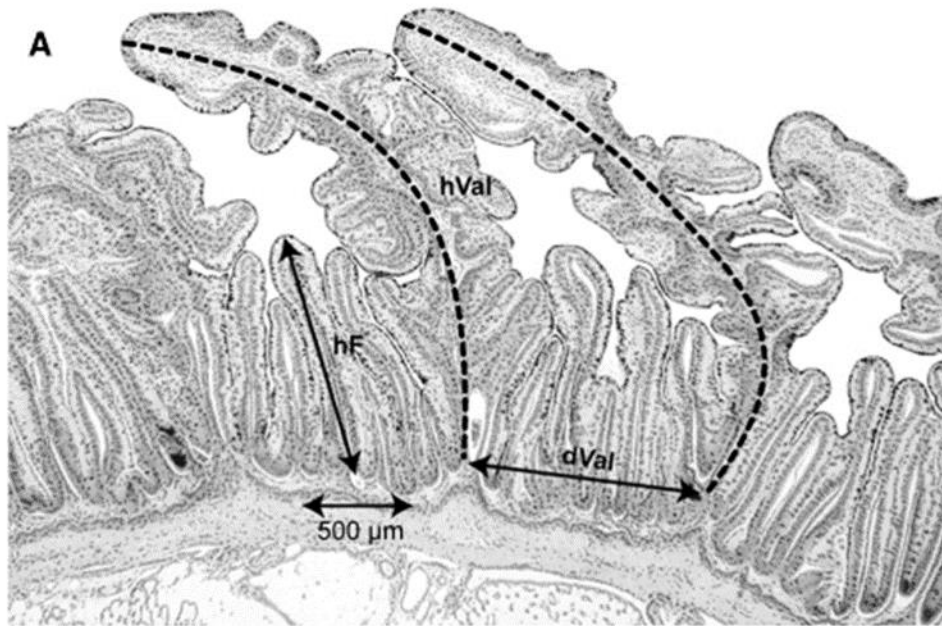
KRKA SOURCE

INTESTINES

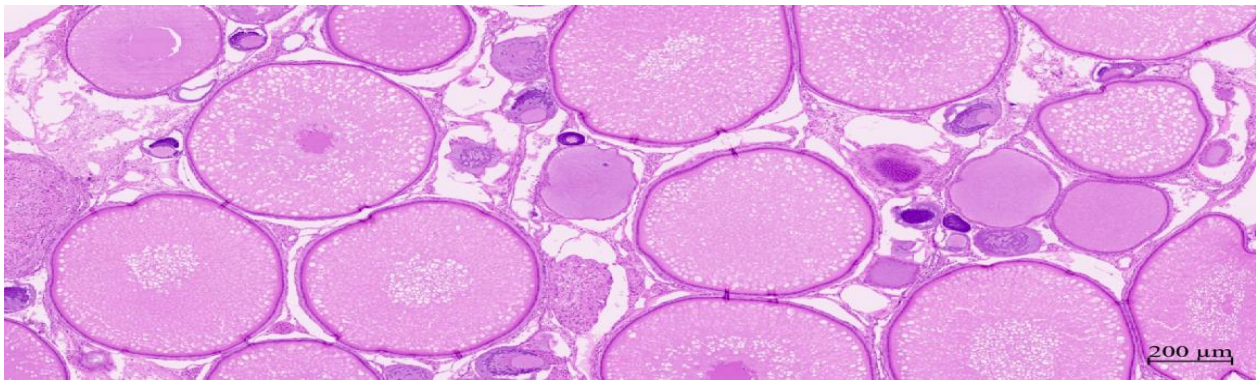
Semiquantitative histopathology

Scoring system	Reaction pattern		
	Control status (I)	Progressive changes (II)	Regressive changes (III)
<i>Lamina epithelialis mucosae</i>	Smooth surface covered with mucous Mucous cells slightly filled with mucous Cellular integrity Supranuclear vacuolization	Hyperplasia and hypertrophy of mucous and epithelial cells	Irregular cell appearance Irregular surface of brush border Cell apartness Nuclear alterations Deposits Eosinophilic granular cells Leucocytes Atrophy/necrosis
<i>Lamina propria mucosae</i>	Developed and thin layer Oval shape nucleus Cells densely packed in uninterrupted circular layer Outside intestinal folds	Hyperplasia and hypertrophy of connective tissue	Cytoplasmic vacuoles Cloudy swelling Deterioration and fragmentation Disjunction Eosinophilic granular cells Leukocyte infiltration Atrophy/necrosis
<i>Lamina muscularis mucosae</i>	Developed and thickened muscle layer Heterogeneous fiber shape Nucleus oval in shape Muscular fibers densely packed in uninterrupted circular layer	Hyperplasia and hypertrophy of smooth muscle fibers	Picnotic nuclei Cytoplasmic vacuoles Clumping of muscle fibers Disrupted myofibril architecture/structure Desquamation of muscle fibers Eosinophilic granular cells Detachment Atrophy/necrosis

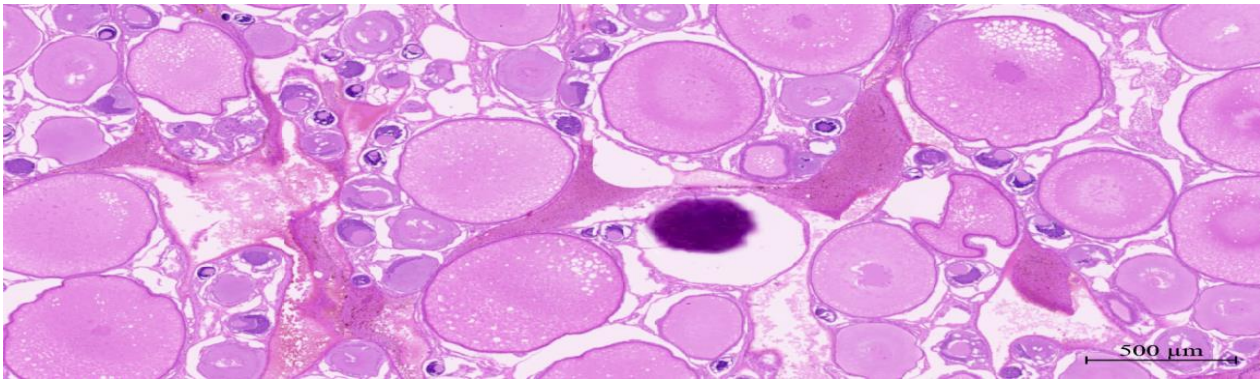
Quantitative histopathology



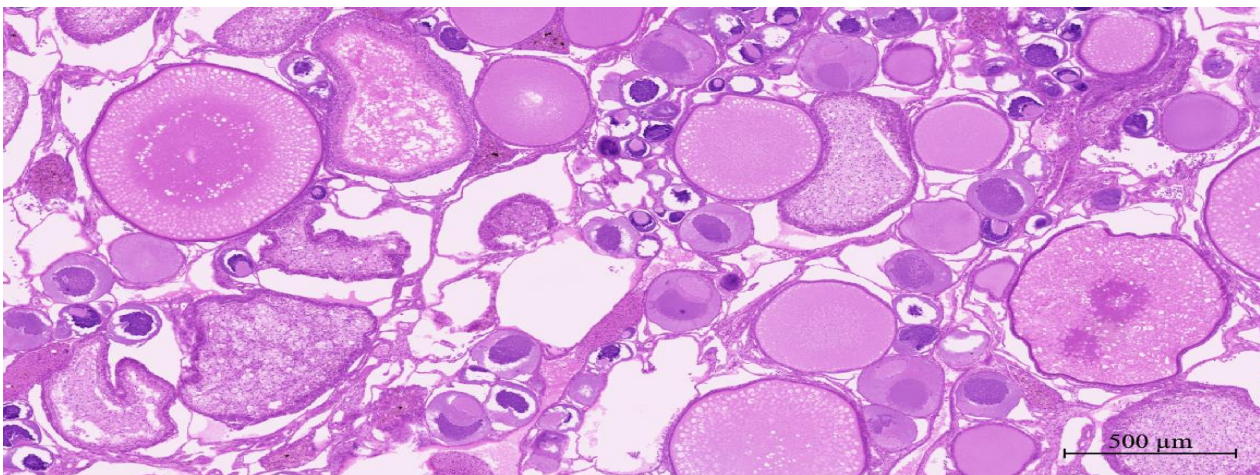
- height of intestinal lumen (hL);
- width of intestinal lumen (wL);
- height of intestinal fold (hF);
- width of intestinal fold (wF);
- total enterocyte height (hE);
- microvillus estimated height (height of the PAS positive stained zone), (hMV);
- height of supranuclear space (hSN);
- nucleus height (hN);
- nucleus width (wN);
- number of enterocyte nucleus over 100 μm fold distance (nNE);
- number of leukocytes over 100 μm fold distance (nL);
- number of granulocytes over 100 μm fold distance (nG);
- number of mucous cells over 100 μm fold distance (nM);
- mucous cell height (hMC);
- mucous cell width (wMC).



MILJACKA (KNP)

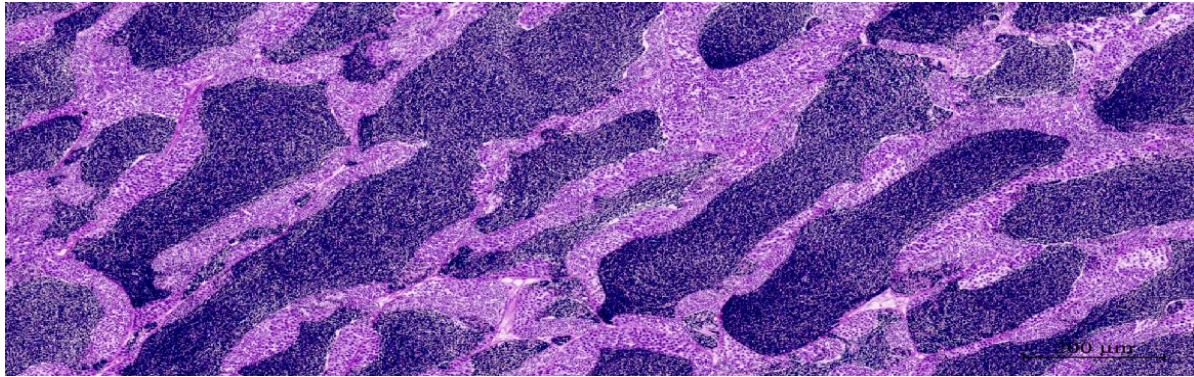


KNIN

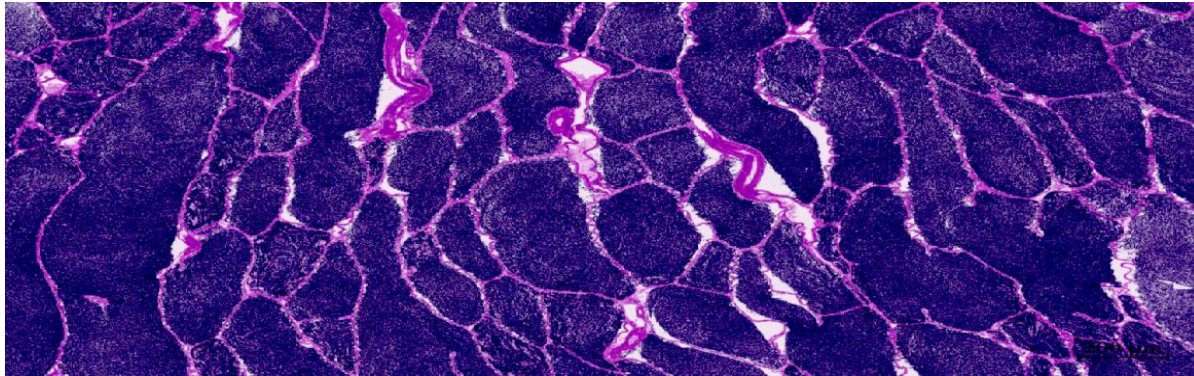


KRKA SOURCE

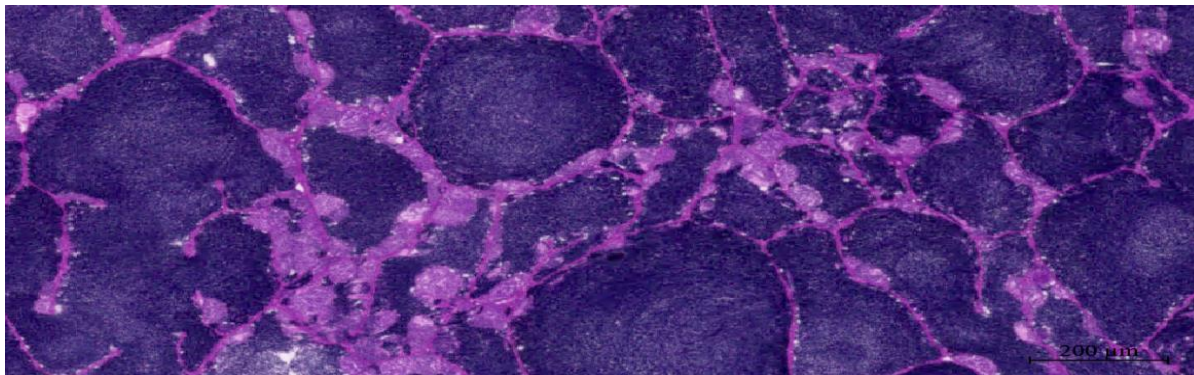
FEMALE GONADS



MILJACKA (KNP)

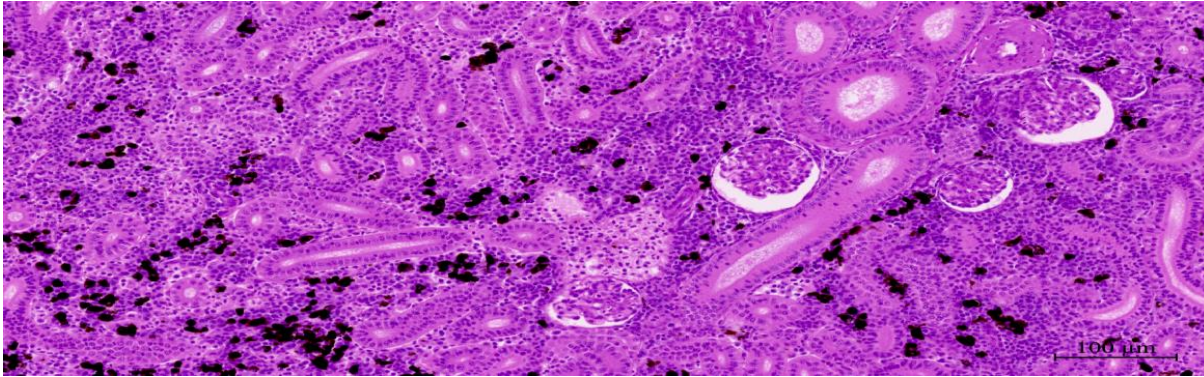


KNIN

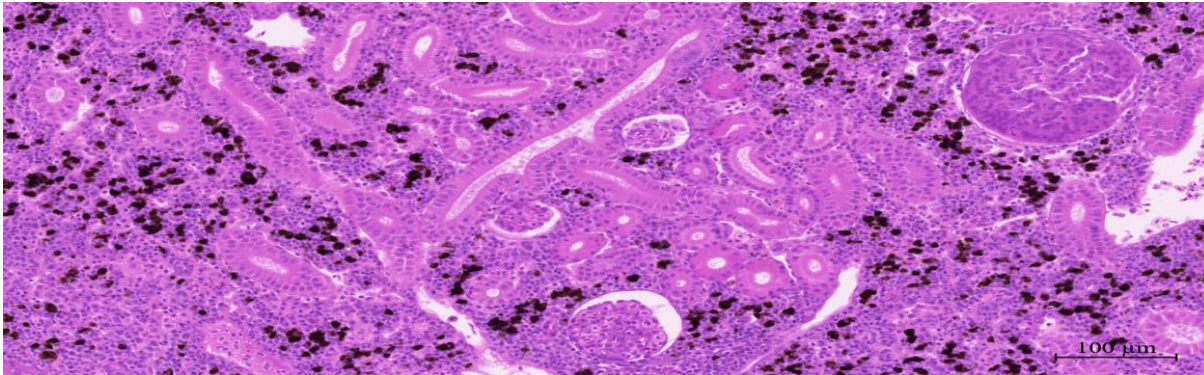


KRKA SOURCE

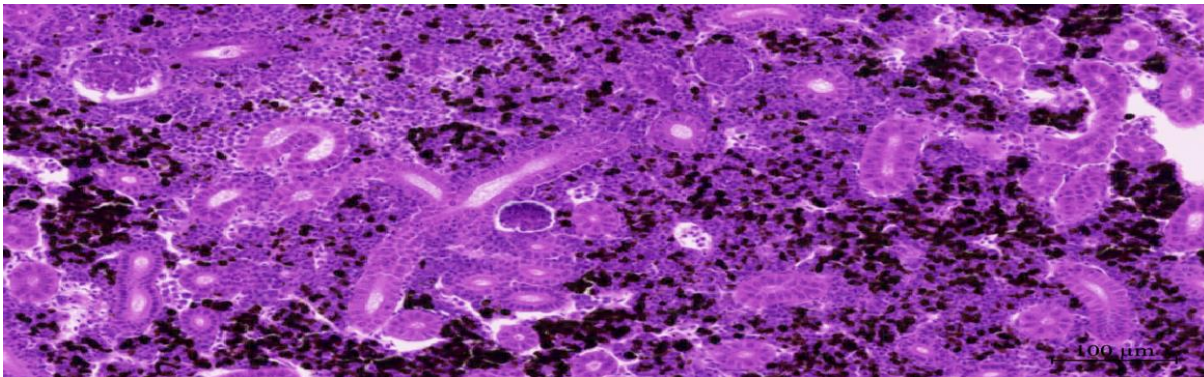
MALE GONADS



MILJACKA (KNP)

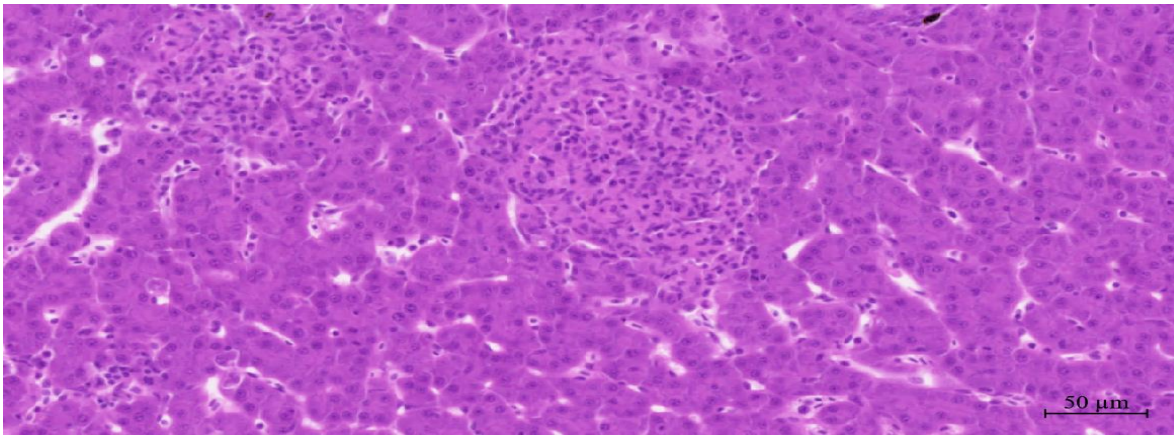


KNIN

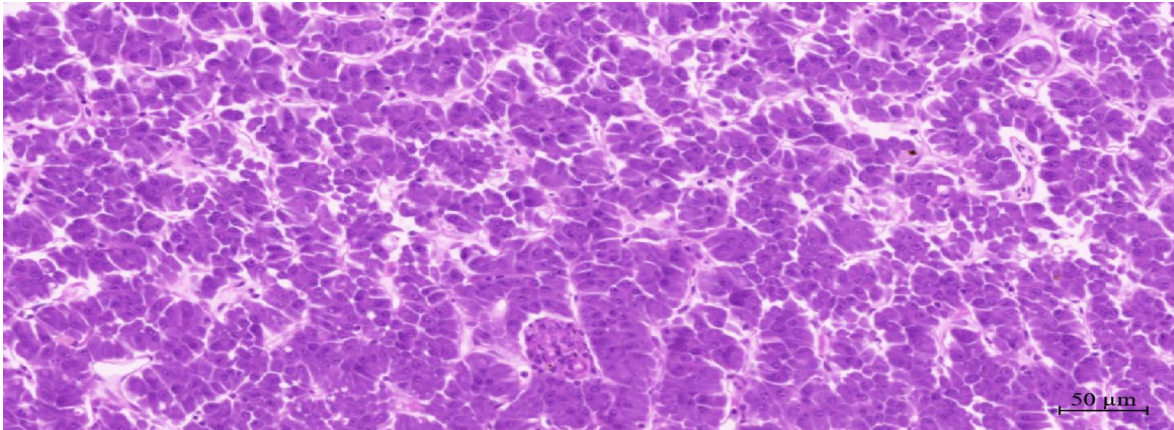


REFERENCE SITE

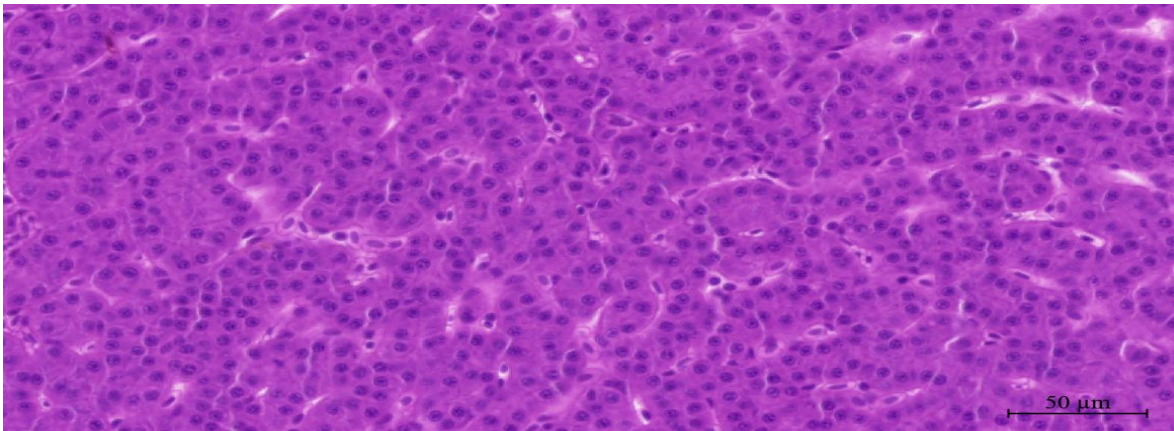
KIDNEY



MILJACKA (KNP)

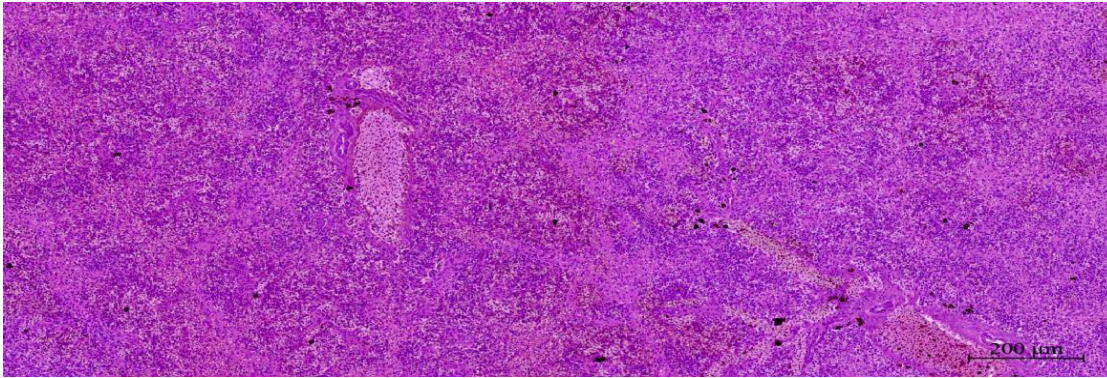


KNIN

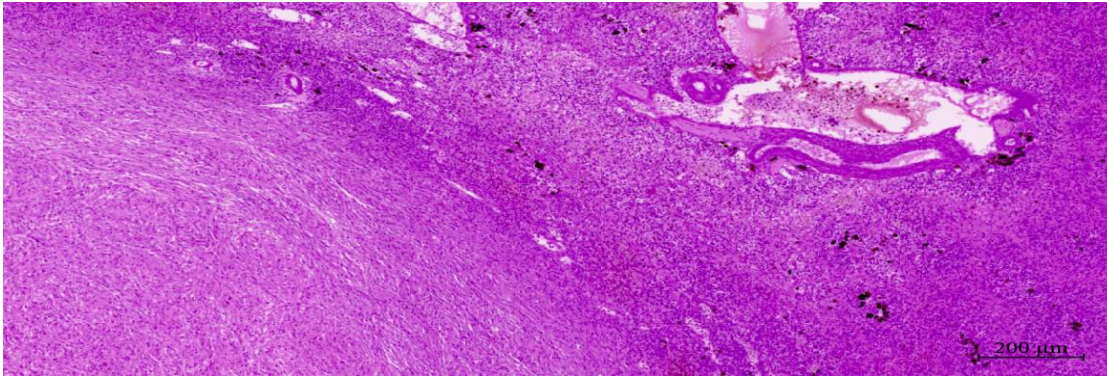


KRKA SOURCE

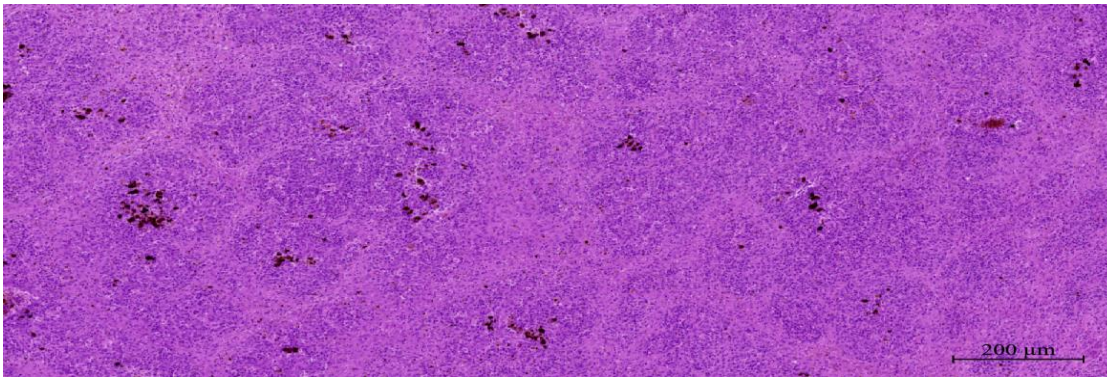
LIVER



**MILJACKA
(KNP)**



KNIN



KRKA SOURCE

SPLEEN

SKIN TUMOUR GROWTH? ACANTOCEPHALA?

